

# We are IntechOpen, the world's leading publisher of Open Access books Built by scientists, for scientists

5,400

Open access books available

133,000

International authors and editors

160M

Downloads

Our authors are among the

154

Countries delivered to

TOP 1%

most cited scientists

12.2%

Contributors from top 500 universities



WEB OF SCIENCE™

Selection of our books indexed in the Book Citation Index  
in Web of Science™ Core Collection (BKCI)

Interested in publishing with us?  
Contact [book.department@intechopen.com](mailto:book.department@intechopen.com)

Numbers displayed above are based on latest data collected.  
For more information visit [www.intechopen.com](http://www.intechopen.com)



# Review of Compartment Syndrome

*Khaled Elawady and Saqeb Mirza*

## Abstract

Compartment syndrome is a painful condition, caused by increased pressure in a closed muscular compartment. A compartment is a group of muscles enclosed in fascia and septa of connective tissue, which separates different muscle groups. The chambers created receive their blood supply through the arteries. As the pressure builds in the closed space, the blood supply to muscles enclosed decreases. Normal compartment pressure allows blood to flow in and then venous outflow to exit the compartment. However, with increased pressure in the compartment, the arterial flow is impaired. Subsequently, venous outflow stops, adding to the volume of the closed chamber, and hence, pressure builds to the point when the arterial flow stops as well. This chapter provides a general overview of the compartment syndrome in orthopaedic surgical practice. It includes definitions, causes, microscopic anatomy and pathophysiology, as well as the management of this condition.

**Keywords:** compartment, syndrome, osteofascial, contracture, fasciotomy, plastics, leg compartments

## 1. Introduction

Compartment syndrome is an acute surgical emergency; it can be limb threatening and potentially life threatening. It results from decreased tissue perfusion secondary to increased pressure within an osteofascial compartment, the consequences of which may result in tissue necrosis. Incidence is more in young men, commonly under 35 years old, and the mean age is different between males (30 years old) and

Males—average age 32 years	91%
Females—average age 44 years	9%
Tibial diaphyseal fracture	36.0%
Soft-tissue injury	23.2%
Distal radial fracture	9.8%
Crush syndrome	7.9%
Diaphyseal fracture of the radius/ulna	7.9%
Femoral fracture	3.0%
Tibial plateau fracture	3.0%

**Table 1.**  
*Compartment syndrome risk factors, adapted from [1].*

females (44 years old). Sixty-four per cent are associated with fractures, with the annual incidence being 1–7.3 per 100,000 [1].

Acute compartment syndrome affects patients involved in trauma and those patients with associated neurologic and other injuries that can mask the diagnosis. A high degree of suspicion, as well as understanding the natural history and limited value of signs and symptoms, will increase the awareness of the possible diagnosis. The following risk factors can aid in making the diagnosis (**Table 1**) [2].

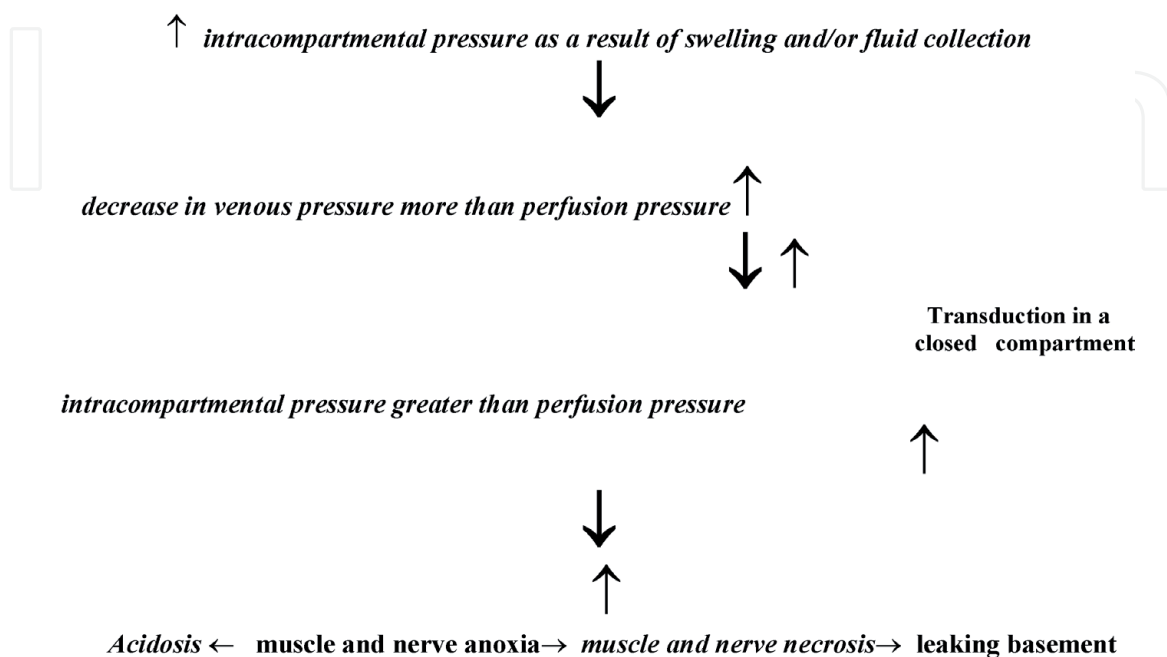
## 2. Pathophysiology

Acute compartment syndrome is caused by an increase in the contents of an enclosed space (e.g. bleeding) or a decrease in the volume of a space (e.g. tight cast), or a combination of the two factors. Intercompartmental pressure (ICP) is a function of and an interaction between interstitial pressure and perfusion pressure at the level of the capillary bed. When the interstitial pressure exceeds the perfusion pressure at capillary bed level, there is increased pressure at the venous end of the capillary bed. The resulting increased hydrostatic pressure and further increased intracompartmental pressure eventually limit arteriolar inflow within the system [3]. As a result, the perfusion pressure reduces and ultimately, the perfusion of the compartment stops, leading to anoxia and death of compartment contents (**Figure 1**).

At a cellular level, diminishing ATP levels correlate closely with worsening muscle necrosis, leading to complete muscle necrosis. In a canine study, after 6 h of ischaemia, only 20% of pre-ischaemic ATP remained, which led to complete muscle necrosis [4].

Histologically, there is central muscle necrosis with a surrounding zone of partial ischaemia and peripheral tissue oedema, often within areas of incomplete injury [1]. Adenosine triphosphate (ATP) breakdown occurs as a result of ischaemic injury to the muscle and the severity of this damage is directly related to the level of energy depletion [5].

### Pathophysiology



**Figure 1.**  
Illustration of pathophysiologic sequence for the development of acute compartment syndrome.

Skeletal muscles are affected by ischaemia more than other body tissues. With regard to susceptibility to muscle ischaemia, red muscle fibres, for example those located in the anterior compartment of the leg, are more vulnerable to the effects of ischaemia due to their predominant reliance on aerobic metabolic energy in contrast to white muscle fibres, for example the gastrosoleus complex that relies on anaerobically derived energy [6, 7]. Injury (the amount of muscle necrosis) is determined by duration of ischaemia, fibre type, the available residual blood flow and temperature at which ischaemia takes place. Increased collateral blood flow and decreased ischaemic temperature lead to less muscle necrosis [8]. Longer time to diagnose and definitive treatment result in progressive skeletal muscle death and the degree of skeletal muscle injury correlate directly with the severity and duration of ischaemia.

### **3. Classification**

The two main types of compartment syndrome exist, acute and chronic (exertional) compartment syndrome.

Acute compartment syndrome occurs following a fracture, crush injuries, severe muscle bruises, tight casts or bandages, bleeding into compartments in patients with coagulation disorders and heavy drinking or drug abuse.

Chronic exertional compartment syndrome follows repetitive exercise motion and occurs most frequently in people under 40. However, it can develop at any age.

Risk increases with exercises such as swimming, tennis or running, and intense or frequent workouts can also increase the risk. The link between exercise and its association with chronic (exertional) compartment syndrome is not fully understood [9].

### **4. Diagnosis**

There are a few situations that put patients at significant risk of developing compartment syndrome and warrant routine observations for compartment syndrome. These include major limb injuries including open or segmental long-bone injuries caused by high-energy mechanisms, operative management of major limb injuries and prolonged surgical procedures that may compromise or affect limb perfusion adversely. In these cases, it should be routine procedure to monitor the limb closely for any signs of evolving compartment syndrome.

The BOAST guidelines recommend meticulous documentation of the clinical findings in suspected compartment syndrome. In addition, it is important to record the mechanism of injury and the time it occurred as well as the initial time of evaluation and ongoing clinical reviews. Pain levels and analgesic requirements should be recorded and whether or not any regional anaesthetics had been used thus far [10].

The most important and diagnostically significant signs include pain on passive stretch of the muscles in the individual compartments affected and pain out of proportion to the injury, and these should be acted upon in a timely manner [1, 2].

Documentation of neural function and vascular perfusion including capillary refill time and pulses need to be recorded and documented even though they have little role in the early and timely diagnosis of an evolving acute compartment syndrome [10].

Classic features including pain, pallor, pulselessness, paraesthesia, poikilothermia and paralysis are more considered late signs of a limb that has been vascularly compromised and do not really play a part in early diagnosis of ACS [11]. Undiagnosed acute compartment syndrome will cause progressive muscle damage.

Therefore, it may be beneficial for one experienced assessor to serially examine the patient, so the evolution of the condition is noted rather than at one point in time and at the same time avoid interobserver error [11, 12].

The presence of all five features may indicate a late diagnosis and irreversible damage because some features such as paralysis occur very late in the pathogenesis of acute compartment syndrome. Frequent serial clinical assessment must be interpreted taking into consideration the patient's individual risk [11].

When compartment pressure measurements are indicated, for example in unconscious patients, the diastolic blood pressure is recorded. If the difference between diastolic blood pressure and compartment pressure is less than 30 mmHg, this suggests an increased risk of compartment syndrome and a decision should be made either to proceed to surgical decompression or to continue monitoring. This decision-making process should involve a senior clinician [10].

Bayes' theorem has been used to calculate the predictive values of some of the cardinal features of acute compartment syndrome. These included pain, paraesthesia, paresis and pain on passive movement of the muscles involved. The high specificity and negative predictive values for these factors suggested that their absence correlated with a less likelihood of the presence of an acute compartment syndrome, but they had a low-positive predictive value indicating that presence of these symptoms on their own had a low correlation with acute compartment syndrome [13].

## **5. Management**

The initial management should involve splitting the plaster dressing to skin level. Studies have shown that removing dressings overlying the compartment suspected of raised ICP, splitting the cast reduced ICP by a mean of 65% [14]. Moreover, a 10–20% further reduction occurred after the padding cut to skin level. However, even after the removal of tight casts, continued monitoring for clinical features of ACS should occur and it is recommended that the limb should not be elevated excessively but rather be maintained at heart level to perfuse the compartment [14].

If acute compartment syndrome clinical features do not regress following this, a fasciotomy indicated and should be carried out as an emergency procedure [15]. In some special situations, fasciotomy may not be indicated, for example in patients who already have muscle death due to muscle crush syndrome suffered in situations such as natural disasters. In these cases, conservative management may be more appropriate in these patients. The decision to proceed with fasciotomy was based on a comprehensive clinical assessment [16].

In certain circumstances, some authors consider primary amputation a better option than decompressive fasciotomy, especially if there has been a duration of greater than 8 h following the onset of symptoms of acute compartment syndrome with absent muscle function [17].

Compartment pressure measurement can be used as an adjunct to clinical examination, especially if the clinical symptoms cannot be elicited, for example in unconscious or ventilated patients, or if clinical examination is equivocal, or unreliable [17].

Serial compartment pressure measurement, with the initial measure used as a reference point, detects a further rise in the compartment pressure [1].

Two standard techniques for compartment pressure measurement are the slit catheter and the side-port needle. The slit catheter is a low-volume infusion technique [18]. The catheter may be left within the compartment for repeated or continuous compartment pressure measurements for hours.

Side-port needles can be used to measure multiple compartments, and studies have shown no significant difference statistically when comparing the measurements taken with a slit catheter or the side-port needle [19].

Using an 18-gauge needle to measure intracompartmental pressure tends to overestimate the value of the intracompartmental pressure by 20 mmHg when compared with the slit catheter method or the side-port needle and may hence be less accurate. Several commercially available pressure measurement devices are available for determining the intracompartmental pressures.

There is a relationship between compartmental tissue pressure and the distance from the site of the fracture. In one study, the highest pressure recorded was in the deep posterior or anterior compartments, or both, and 89% of compartments had the highest pressure measurement at the fracture site [20].

Once an impending or confirmed compartment syndrome diagnosis has been made, immediate measures necessary must be taken to reduce the chances of progression. These include splitting or taking any casts or occlusive dressings off. Cast padding or circumferential dressings have to be released around their entire circumference, and the limb has to be elevated to the level of the patient's heart to maximise perfusion while minimising swelling. If, in spite of these steps, the clinical signs of compartment syndrome do not resolve, emergent and complete fasciotomy of all compartments with elevated pressures is necessary.

Patients should be counselled about the risks associated with fasciotomy such as wound healing problems, weakness, chronic venous insufficiency, non-union of the associated fractures and subsequent plastic surgical intervention, for example skin grafting.

There are several techniques of decompression for different parts of the body.

### 5.1 Forearm compartment syndrome

There are three compartments: the volar compartment (superficial and deep), dorsal compartment and mobile wad of Henry (lateral) compartments.

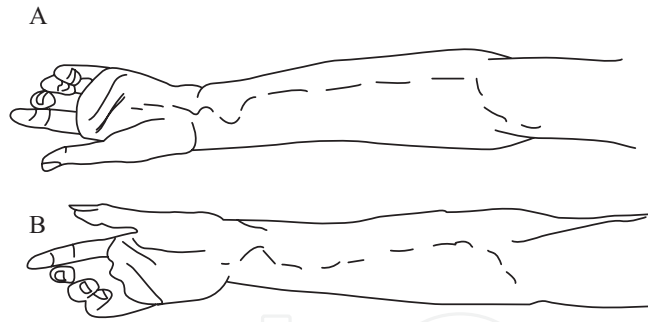
Decompression of all involved compartments is mandatory, involves a volar incision 1 cm proximal and 2 cm lateral to the medial epicondyle and obliquely crosses the antecubital fossa and over the volar aspect of the mobile wad, and then curves medially, reaching the midline at the junction of the middle and distal third of the forearm and continued just medial to the palmaris longus tendon to avoid the palmar cutaneous branch of the median nerve incision, crossing the wrist crease at an angle and extending into the mid-palm for a carpal tunnel release if necessary (Figure 2).

The lacertus fibrosus and fascia overlying the flexor carpi ulnaris must be opened and flexor carpi ulnaris is retracted ulnarly, and the flexor digitorum superficialis is retracted radially to permit opening of the fascia of the deep volar compartment, avoiding the ulnar nerve and artery carefully during dissection.

Dorsal compartment release is through a longitudinal incision 2 cm distal to the lateral epicondyle towards the midline of the wrist, dissecting between the interval of extensor digitorum communis and extensor carpi radialis brevis. The muscles of the forearm should be palpated and if soft, no further procedure should be performed. If residual muscle tension is felt, then an epimysiotomy is performed.

### 5.2 Hand compartment syndrome

In the hand, 10 compartments may be affected by rising compartment pressures. They are hypothenar, thenar, adductor pollicis, dorsal interosseous (four) and volar interosseous (three).



**Figure 2.**  
*Illustration of the incisions used to decompress the volar forearm.*

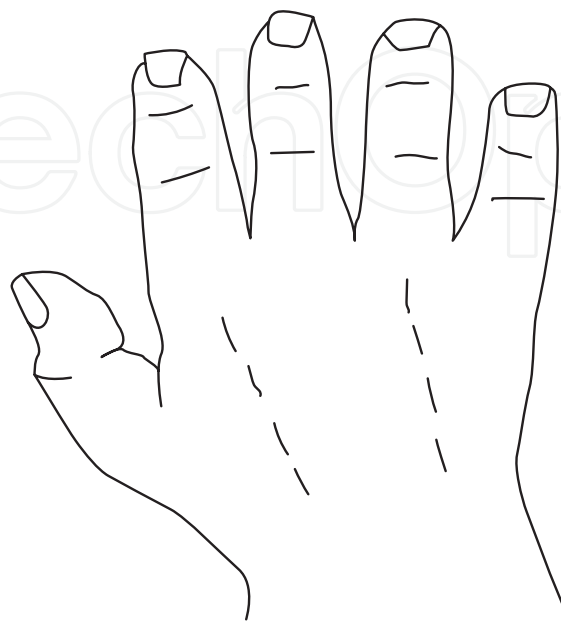
Release of the volar and dorsal interosseous compartments and the adductor compartment to the thumb is done with two longitudinal incisions dorsally over the second and fourth metacarpals (**Figure 3**).

Incising the fascia over the dorsal interosseous muscles and blunt dissection is performed along the ulnar side of the second metacarpal to decompress the first volar interosseous through the more radial incision, and the radial aspect of the fourth and fifth metacarpals is dissected through an ulnar incision to release the second and third volar interosseous compartments. For releasing the thenar and hypothenar compartments, longitudinal incisions are made at the junctions of the glabrous and non-glabrous skin over the radial side of the first metacarpal and the ulnar side of the fifth metacarpal.

Ideally, hand fasciotomies should be done by a hand surgeon unless there is an immediate need with no access to a hand surgeon [21].

Various locations in the lower extremity can develop compartment syndromes, for example the gluteal musculature, the muscles of the thigh and lower leg, and foot.

Early recognition and decompression are the key to avoid long-term complications and even amputation of the limb.



**Figure 3.**  
*Drawing of the two incisions used for the hand compartment decompression.*

### 5.3 Gluteal musculature

Posterior incision decompresses the gluteus maximus and the abductor musculature used sufficiently to decompress the gluteal region.

### 5.4 Thigh compartment syndrome

A long single lateral incision can sufficiently decompress the anterior and posterior compartments of the thigh. A medial adductor incision may be required if ongoing symptoms of increased compartment pressure are evident despite adequate decompression through the long lateral incision.

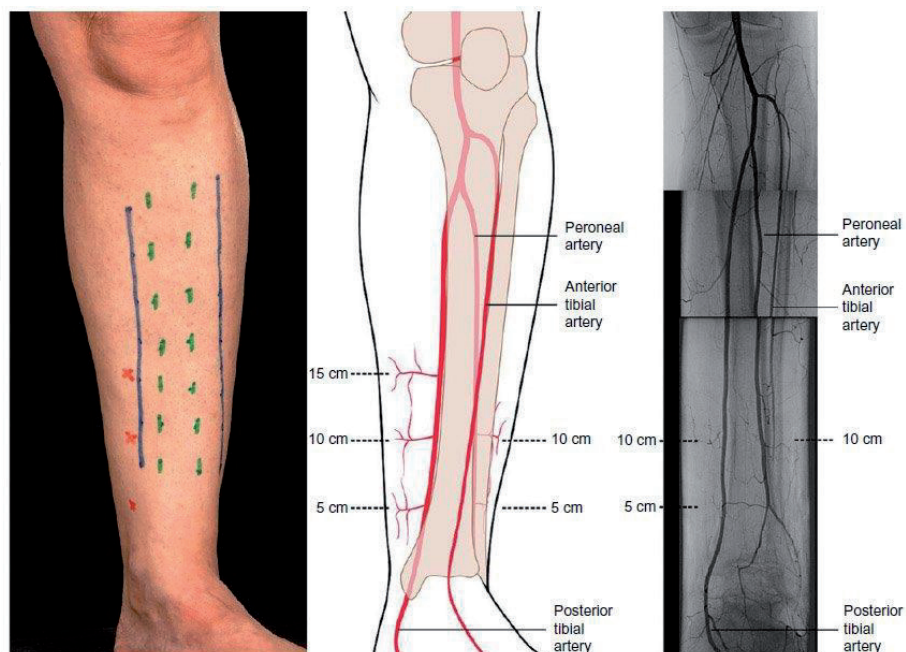
### 5.5 Leg compartment syndrome

The length of the skin incision influences fascial decompression in the leg associated with an acute compartment syndrome, to normalise the compartment pressures and restore perfusion to the tissues. Some authors favour limited incisions, claiming low morbidity, while others recommend long incisions, emphasising that these are required to decompress the affected compartment adequately [17].

In a trauma situation, long incisions are recommended for adequate decompression. Hyperaemia post-decompression is avoided by using long incisions to prevent the skin from creating a tight compartment envelope [22].

Leg decompression can be done *via* a one-incision or a two-incision approach.

The one-incision technique, although described, is difficult and not widely used. It involves a long single lateral incision over the anterolateral leg made 5 cm distal to the head of the fibula and proximal to the lateral malleolus [22]. This is followed by identifying the septum between the anterior and lateral compartments and avoiding the injury to the superficial peroneal nerve distally, the anterior and lateral compartments on either side of the septum are decompressed [23].



**Figure 4.** Two-incision fasciotomies; the medial incision alone is usually sufficient for debridement and preserves the perforators arising from the posterior tibial vessels, which form the basis of local fasciocutaneous flaps.



Then, the lateral compartment musculature is lifted from the intramuscular septum and incising the intramuscular septum to access the lateral portion of the superficial posterior compartment, and through this incision, the deep posterior compartment can be decompressed by mobilising the superficial compartment posteriorly [17].

The more widely used and accepted approach is a two-incision technique (**Figure 4**), and this is the approach recommended in the UK BOAST/BAPRAS guidelines.

The location of the medial skin incision is crucial as muscles in the superficial posterior compartment are proximal and the incision needs to reach the proximal part of the deep posterior compartment to decompress these muscles adequately.

The leg deep posterior musculature is on the other hand in the distal half of the limb and decompressing them involves detaching the soleus origin from the medial aspect of the tibial shaft. Extra care is taken at this point as posterior tibial neurovascular bundle lies just deep to the investing fascia. A careful assessment of muscle viability is needed, and all non-viable muscles should be excised.

It should be noted that the lateral incision, if inadvertently placed over the fibula (too lateral), can expose the periosteum, and if placed too far distally, the incision can expose the peroneal tendons, exposing bone and/or tendons increase incidence of infection and delayed healing, and may end in amputation [20].

## 5.6 Foot compartment syndrome

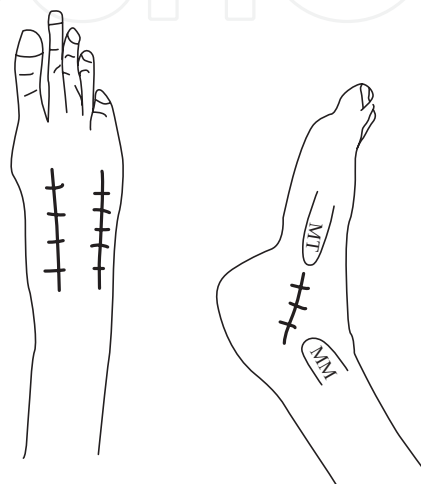
Foot compartment syndrome is a controversial subject, as some foot and ankle specialists advocate not interfering surgically due to the associated morbidity with surgery.

In the foot, there are nine main compartments: medial, lateral, interosseous (four) and central (three), and dual dorsal incisions are recommended for decompression of the foot compartments (**Figure 5**).

A dorsal medial incision is made medial to second metatarsal, and this releases the first and second interosseous, medial and deep central compartment.

The dorsal lateral incision is made lateral to the fourth metatarsal and releases the third and fourth interosseous, lateral, superficial and middle central compartments.

To do this, the dorsal fascia of each interosseous compartment is opened longitudinally, muscles stripped from the medial fascia of the first interosseous compartment, split adductor compartment and a medial incision may be added



**Figure 5.**  
*Drawing depicts the two dorsal and medial incisions used to decompress the foot compartments.*

for decompression of calcaneal compartment with the release of the fascia of the intrinsic foot muscles at their metatarsal attachments [24, 25].

## 6. Conclusion

Acute compartment syndrome is an acute limb-threatening condition. Its diagnosis is mainly clinical and involves certain cardinal features. A high index of suspicion is needed to make the diagnosis. The condition is time critical and timely surgical intervention is the key to success.

## Abbreviations

ICP	intracompartmental pressure
ACS	acute compartment syndrome

## Author details

Khaled Elawady<sup>1\*</sup> and Saqeb Mirza<sup>2</sup>

<sup>1</sup> Oxford University Hospital, UK

<sup>2</sup> University Hospital of Wales, UK

\*Address all correspondence to: [kaledawady@gmail.com](mailto:kaledawady@gmail.com)

## IntechOpen

© 2021 The Author(s). Licensee IntechOpen. This chapter is distributed under the terms of the Creative Commons Attribution License (<http://creativecommons.org/licenses/by/3.0>), which permits unrestricted use, distribution, and reproduction in any medium, provided the original work is properly cited. 

## References

- [1] McQueen MM, Gaston P, Court-Brown CM. A molecular interaction database. Acute compartment syndrome. Who is at risk? *The Journal of Bone and Joint Surgery. British Volume.* 2000;**82**(2):200-203
- [2] McQueen MM, Christie J, Court-Brown CM. Compartment pressures after intramedullary nailing of the tibia. *The Journal of Bone and Joint Surgery. British Volume.* 1990;**72**:395-397
- [3] Tiwari A, Hag AI, Myint F, et al. Acute compartment syndromes. *Journal of British Surgery.* 2002;**89**:397-412. DOI: 10.1046/j.0007-1323.2002.02063.x
- [4] Hayes G, Liauw S, Romaschin A, et al. Separation of reperfusion injury from ischemia-induced necrosis. *Surgical Forum.* 1988;**39**:306-308
- [5] Lindsay T, Liauw F, Romaschin S, et al. The effect of ischemia/reperfusion on adenine nucleotide metabolism and xanthine oxidase production in skeletal muscle. *Journal of Vascular Surgery.* 1990;**12**:8-15
- [6] Blaisdell FW. The pathophysiology of skeletal muscle ischemia and the reperfusion syndrome: A review. *Cardiovascular Surgery.* 2002;**10**:620-630. DOI: 10.1016/S0967-2109(02)00070-4
- [7] Jennische E. Ischemia-induced injury in glycogen-depleted skeletal muscle: Selective vulnerability of the FG-fibres. *Acta Physiologica Scandinavica.* 1985;**125**:727-734. DOI: 10.1111/j.1748-1716.1985.tb07776.x
- [8] Petrasek PF, Homer-Vanniasinkam S, Walker PM. Determinants of ischemic injury to skeletal muscle. *Journal of Vascular Surgery.* 1994;**19**:623-631. DOI: 10.1016/S0741-5214(94)70035-4
- [9] Bae DS, Kadiyala RK, Waters PM. Acute compartment syndrome in children: Contemporary diagnosis, treatment, and outcomes. *Journal of Pediatric Orthopaedics.* 2001;**21**:680-688. DOI: 10.1097/00004694-200109000-00025
- [10] BOAST British Orthopaedic Association Standards for Trauma. Review date: December 2016. For correspondence, contact: policy@boa.ac.u
- [11] Malik AA, Khan WS, Chaudhry A, et al. Acute compartment syndrome a life and limb-threatening surgical emergency. *Journal of Perioperative Practice.* 2009;**19**(5):137-142
- [12] Shuler FD, Dietz MJ. Physicians' ability to manually detect isolated elevations in leg intracompartmental pressure. *The Journal of Bone & Joint Surgery.* 2010;**92**(2):361-367
- [13] Ulmer T. The clinical diagnosis of compartment syndrome of the lower leg: Are clinical findings predictive of the disorder? *Journal of Orthopaedic Trauma.* 2002;**16**(8):572-577
- [14] Köstler W, Strohm PC, Südkamp NP. Acute compartment syndrome of the limb. *Injury.* 2004;**35**(12):1221-1227
- [15] Murphy JB. Myositis. *JAMA: The Journal of the American Medical Association.* 1914;**63**:1249
- [16] Mubarak SJ, Hargens AR. Acute compartment syndromes. *Surgical Clinics of North America.* 1983;**63**(3):539-565
- [17] Olson SA, Glasgow RR. Acute compartment syndrome in lower extremity musculoskeletal trauma. *Journal of the American Academy of Orthopaedic Surgeons.* 2005;**13**(7):436-444

- [18] Shakespeare DT, Henderson NJ, Clough G. The slit catheter: A comparison with the wick catheter in the measurement of compartment pressure. *Injury*. 1982;**13**:404-408
- 10.5435/00124635-201101000-00006.  
Erratum in: *J Am Acad Orthop Surg*. 2011 May;**19**(5):50A. PMID: 21205767.
- [19] Moed BR, Thorderson PK. Measurement of intracompartmental pressure: A comparison of the slit catheter, side-ported needle, and simple needle. *The Journal of Bone and Joint Surgery: American Volume*. 1993;**75**: 231-235
- [20] Heckman MM, Whitesides TE Jr, Grewe SR, et al. Compartment pressure in association with closed tibial fractures: The relationship between tissue pressure, compartment, and the distance from the site of the fracture. *The Journal of Bone and Joint Surgery. American Volume*. 1994;**76**:1285-1292
- [21] Ouellette EA. Compartment syndromes in obtunded patients. *Hand Clinics*. 1998;**14**(3):431-450
- [22] Cohen MS, Garfin SR, Hargens AR, et al. Acute compartment syndrome: Effect of dermatomy on fascial decompression in the leg. *The Journal of Bone and Joint Surgery. British Volume*. 1991;**73**:287-290
- [23] Purcell D, Terry BA, Sharp BR. Acute compartment syndrome. In: Purcell D, Chinai S, Allen B, Davenport M, editors. *Emergency Orthopedics Handbook*. Cham: Springer; 2019. DOI: 10.1007/978-3-030-00707-2\_3
- [24] Sigamoney K, Khincha P, Badge R, et al. Compartment syndrome: Challenges and solutions. *Orthopedic Research and Reviews*. 2015;**7**:137-148. DOI: 10.2147/ORR.S50776
- [25] Prasarn ML, Ouellette EA. Acute compartment syndrome of the upper extremity. *J Am Acad Orthop Surg*. 2011 Jan;**19**(1):49-58. doi: